

# DISLOCATED POSTERIOR CHAMBER IOLs

BY NICOLE R. FRAM, MD; RICHARD L. LINDSTROM, MD; CATHLEEN M. McCABE, MD;  
AND AUDREY R. TALLEY ROSTOV, MD

## CASE PRESENTATION

A 77-year-old white man underwent bilateral cataract surgery in the early 1990s. The patient is referred to you for an evaluation of dislocated IOLs. He is experiencing double vision and decreased visual acuity in both eyes. The patient's astigmatism is growing, likely due to the dislocated IOLs and increasing dysphotopsia. He notes that his vision is variable, especially in his left eye, "as if something is moving around" in there.

Currently, the patient's BCVA measures  $-7.50 +2.00 \times 165 = 20/25$  OD and  $-7.00 +1.50 \times 145 = 20/40$  OS. The slit-lamp examination is remarkable for a dislocated PMMA IOL in the right eye, with inferior displacement and posterior tilt (Figure 1). The remarkable finding in the left eye is an inferiorly dislocated PMMA IOL

with a Prolene haptic that appears to be partially in the sulcus and partially in the bag (Figure 2). The remainder of the examination is unremarkable. The retinal examination reveals a few drusen but no cystoid macular edema (CME) or other significant change, and optical coherence tomography is normal.

The patient dislikes his 7.00 D of myopia and would like to be less nearsighted after surgery. He states that he would like to retain some myopia, however, for reading.

How would you approach this case? Would you suture the current IOL(s) or perform an IOL exchange? How would you address this patient's refractive desire?

—Case prepared by Audrey R. Talley Rostov, MD.

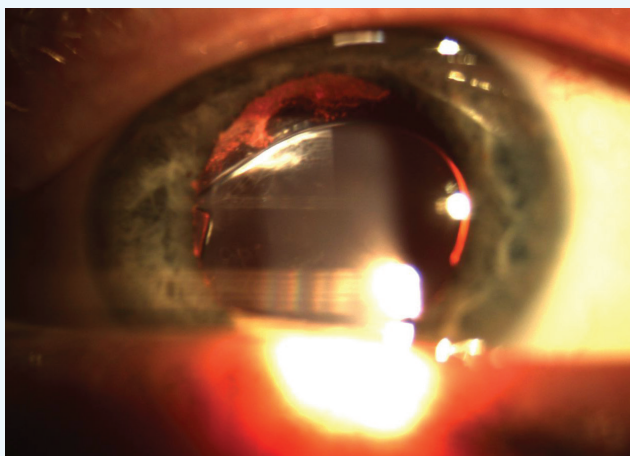


Figure 1. The PMMA IOL in the patient's right eye has dislocated inferiorly and exhibits posterior tilt.

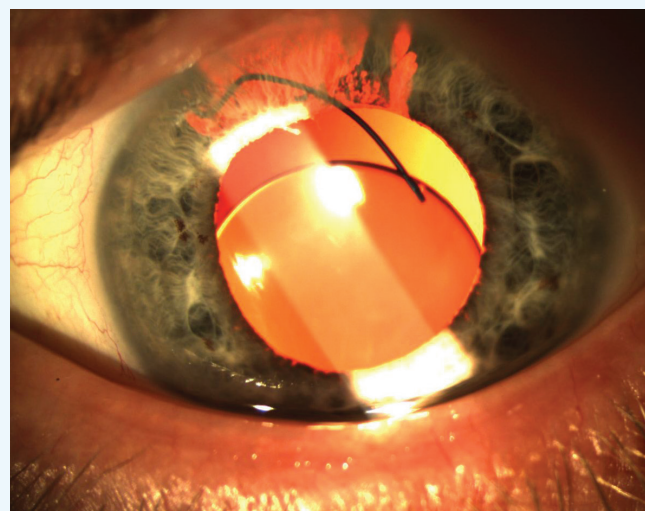
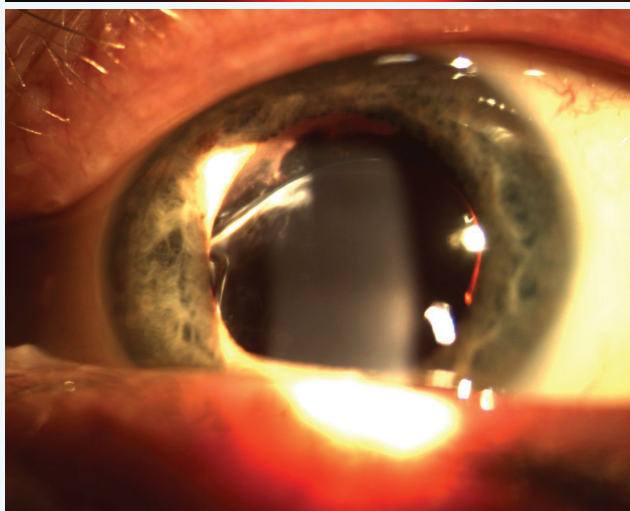


Figure 2. The PMMA IOL in the patient's left eye has dislocated. The Prolene haptics have dislocated inferiorly; one is in the sulcus and the inferior haptic in the bag. Note the superior iris atrophy.



### NICOLE R. FRAM, MD

The current case is representative of malpositioned posterior chamber IOLs (PCIOLs) that are causing visual discomfort with an undesired and fluctuating refractive outcome. According to the case presentation, this patient is experiencing diplopia, increased refractive astigmatism, and decreased visual acuity. Assuming that his diplopia is monocular, it seems likely that the tilted IOL is contributing to the symptoms of double vision and increased astigmatism. In his left eye, a three-piece PMMA PCIOL with a kinked haptic in the sulcus is causing significant superior iris transillumination defects.

Given the patient's relatively young age and discontent with his refractive outcome, I would recommend staged removal and replacement of the IOL in each eye. Fortunately, the patient would like his refractive result to be aimed for near, a much easier target in any IOL exchange procedure. I routinely perform preoperative ultrasound biomicroscopy to evaluate the IOL-bag complex and related pathology in preparation for surgery.

Unfortunately, PMMA PCIOLs cannot be bisected with intraocular scissors, and their removal requires a large scleral tunnel incision (approximately 7 mm). Depending on the PMMA lens, the optic ranges in size from 5 to 7 mm, which the incision needs to accommodate. An ideal targeted refractive outcome would be -2.00 D in both eyes. I would start with the patient's left eye, because the three-piece PMMA PCIOL will likely rotate readily into the anterior chamber and prove the easier of the two to remove, resulting in faster visual recovery.

The case should begin with a superior or temporal (depending on the surgeon's preference) scleral tunnel, carefully fashioned so as not to enter the anterior chamber until the IOL has been repositioned in the anterior chamber. I would then make multiple paracenteses for access (at 11, 2, 5, and 8 o'clock) and instill a dispersive ophthalmic viscosurgical device (OVD) to protect the corneal endothelium. With a Sinskey hook and microsurgical instruments, I would rotate the IOL into the anterior chamber via a bimanual technique and remove the lens through the completed scleral tunnel incision.

If there is more than 270° of anterior capsular support, I would place a silicone or Collamer (STAAR Surgical) three-piece PCIOL in the ciliary sulcus, elevate the optic above the iris, instill acetylcholine (Miochol-E; Bausch + Lomb), and suture the haptics with 10-0 polypropylene or polyester for stability in a McCannel or Siesper fashion, the haptics oriented at 3 and 9 o'clock, away from the superior iris atrophy. If anterior capsular support is tenuous, I would perform a thorough pars plana, triamcinolone-assisted, anterior vitrectomy and scleral suture fixate a CZ70BD PMMA lens (Alcon) or an Akreos AO60 hydrophilic acrylic IOL (Bausch + Lomb) using Gore-Tex (CV-8 thread, off label) via needleless recovery (to be described further).

Once the patient's left eye was stable, I would rehabilitate his right eye. If the IOL could be rotated into the anterior chamber and removed without disturbing the IOL-bag complex, then my plan for the IOL exchange would be similar to that for his left eye. Surgery on the patient's right eye may prove to be more complicated, however, if the haptics are fibrosed within the capsular bag with a significant Soemmering ring. Compared with single- or three-piece acrylic PCIOLs, the haptics of a PMMA lens are more difficult to amputate and should not be cut with microsurgical scissors, because the scissors will be damaged. PMMA haptics can be amputated with long Vannas scissors or Stern-Gills scissors if the surgeon carefully leaves the sharp edge within the capsular bag. It is important to note that a sharp, exposed edge cannot be left in the sulcus, or it will chafe the iris and cause pigment dispersion. I would then suture a three-piece PCIOL to the iris to avoid future decentration.

An alternative and more involved approach would be to remove the entire PCIOL-bag complex. For this procedure, the scleral tunnel should be approximately 8 to 9 mm to accommodate the IOL-bag complex in the event of a large Soemmering ring. If the IOL cannot be freed from the capsular bag without causing significant trauma, the entire IOL-bag complex should be removed with a careful pars plana-assisted anterior vitrectomy to release the remaining zonular attachments and prevent inadvertent traction on the anterior vitreous attachments. Depending on the skill and comfort of the anterior segment surgeon, the assistance of a retina colleague may be necessary. After the IOL's removal and a complete anterior vitrectomy, a CZ70BD or AO60 lens could be sutured to the sclera using Gore-Tex (CV-8 thread, off label) via needleless recovery.

For this procedure, the surgeon marks the site of the sclerotomies 180° apart to ensure proper IOL centration. Conjunctival peritomies are fashioned vertically or horizontally, depending on the scleral tunnel's location. An anterior chamber maintainer is essential to avoid hypotony during intraocular manipulations, and the use of copious amounts of a dispersive OVD is necessary to protect the corneal endothelium. Four sclerotomies are made 2 mm posterior to the limbus and 4 to 5 mm apart using a 23-gauge microvitrectomy blade or the equivalent. The needles are cut off the Gore-Tex suture and loaded onto the CZ70BD IOL's haptic around the islet in a cow-hitch formation, or they are loaded through the four haptics of the AO60 lens for four-point fixation. The surgeon retrieves the suture through the sclerotomies via needleless recovery using microsurgical forceps and ties the suture in a 2-1-1-1 knot or slipknot. The knots and suture ends are then buried into a sclerotomy opening. The conjunctival peritomies are closed with fibrin glue. The ophthalmologist must carefully confirm that the sclerotomies are not leaking. If there is significant subconjunctival chemosis during hydration of the corneal incisions, then the sclerotomies should be sutured to avoid postoperative hypotony.

Most importantly, the patient should be prepared for regular follow-up visits to evaluate his IOP, corneal edema, and retina.



#### **RICHARD L. LINDSTROM, MD**

The single-piece PMMA PCIOL in the patient's right eye exhibits mild inferior decentration and posterior tilt. I see no evidence of iris chafing or inflammation. The patient sees 20/25 with macular drusen. I would initially leave this IOL alone.

The three-piece PMMA IOL in his left eye demonstrates more severe decentration with significant posterior iris chafing, iris pigment epithelium loss, and transillumination defects. Surgical repair is indicated. The 20/40 visual acuity is a concern, but optical coherence tomography is said to be normal except for drusen. I would look carefully for an epiretinal membrane or mild CME. I would also obtain specular microscopy on both eyes preoperatively. I would not be surprised to find a low endothelial cell count, especially in the left eye. I would perform careful gonioscopy as well.

The patient wants to read without glasses, and the IOL in his left eye is not ideal for suturing to the iris or sclera. I would therefore plan an IOL exchange. I cannot see capsular remnants, but they are said to be present, at least inferiorly. I would recommend an IOL exchange and target a result of -4.00 D. I would plan the incisional axis for 145° and start with a 6-mm corneoscleral incision, which would allow removal of the single-piece PMMA IOL and implantation of a single-piece anterior chamber IOL (ACIOL) or a sutured PMMA PCIOL.

The options for the IOL and its fixation include an ACIOL, a PCIOL sutured to the iris, or a PCIOL sutured to the sclera. I would decide at the time of surgery. I would use only intracameral nonpreserved lidocaine (Xylocaine; AstraZeneca) and epinephrine for pupillary dilation to allow good pupillary constriction with an intracameral miotic, if desired.

I would fill the anterior chamber with an OVD, likely Viscoat (Alcon). Using a Kuglen hook, I would retract the iris and examine the IOL and capsular anatomy. If the retained capsule suffices, I would simply rotate the old IOL free inferiorly, remove it with dispersive viscoelastic in front of and behind the IOL, and place a new single-piece PMMA PCIOL in the sulcus. If I were at all concerned that capsular support might be inadequate, I would suture the IOL's haptics to the iris using a standard approach with 10-0 polyester. I like the CZ70BD lens and the P366UV IOL (Bausch + Lomb). In some instances, I have performed an iridoplasty with suturing for a severe transillumination defect, but in this case, the upper eyelid should mitigate any symptoms.

Transscleral fixation is another but somewhat more invasive option, with a higher complication rate. Properly placed, an ACIOL with a superior iridotomy would also be a reasonable option for this elderly patient.

If a vitrectomy were required, I would use a bimanual approach via the pars plana. I always use intraocular triamcinolone acetate to help me visualize vitreous and reduce postoperative inflammation.



#### **CATHLEEN M. MCCABE, MD**

In this case, an IOL exchange is the most appropriate management, given the patient's desire to be less myopic. The extensive iris atrophy and the reported sensation of movement in his left eye, combined with decreased BCVA (20/40), makes me suspect CME as a result of chronic uveitis, although no CME was

noted. To best achieve the patient's refractive goals, corneal astigmatism should be measured and limbal relaxing incisions performed at the time of the lens exchange. Locating the incision at the steep axis of the cornea will also help to minimize postoperative astigmatism. A contact lens trial could help determine the appropriate refractive goal, with a -1.75 to a -2.00 D result in both eyes allowing for comfortable reading vision. Monovision would be less desirable because of the compromised vision in the patient's left eye.

If the current lens can be carefully dialed out of the capsular bag and removed from the eye while leaving adequate capsular support, the new lens can be placed in the sulcus. In this case, however, the capsular support is likely to be inadequate in the left eye, given the movement noted by the patient. A 23-gauge pars plana vitrectomy will be necessary to prevent traction on the vitreous during removal of the lens-capsule complex. The new lens would then be introduced into the sulcus. The haptics would be externalized under partial-thickness scleral flaps and glued in place using the technique described by Agarwal and others. A STAAR Elastimide lens (AQ2010V; STAAR Surgical) or the Sofport lens (LI61AO; Bausch + Lomb) are suitable choices, given their long, posteriorly angulated haptics. In my experience, the Sofport inserter provides a gentle, controlled, planar entry into the eye. Scleral fixation with this method would best protect against further iris chafing.



#### **WHAT I DID:**

##### **AUDREY R. TALLEY ROSTOV, MD**

The IOL appeared to be fairly stable in the patient's right eye, which had good BCVA. He had decreased visual acuity in his left eye, however, with a clearly dislocated IOL, transillumination defects, and complaints of diplopia. For these reasons, I chose to operate on the patient's left eye and targeted a postoperative refraction of -3.50 D.

After creating bimanual incisions with a diamond blade, I injected a dispersive OVD (Viscoat) into the anterior chamber and then injected a cohesive OVD under the IOL. I used a Kuglen hook and microforceps to maneuver the IOL into the

anterior chamber. I made a corneoscleral incision temporally and extended it to 6 mm, after which I was able to explant the PMMA IOL without difficulty. An examination of the capsular remnants revealed very little capsular support—inadequate for a sulcus-fixated IOL. Because I had already created a large incision for explanation of the PMMA IOL, and given the patient's age, I decided to implant an MT3AO ACIOL (Alcon) after instilling acetylcholine (Miochol-E) and performing a small, superior peripheral iridotomy. Next, I removed the OVD via irrigation and aspiration, and I sutured the wound with two 10-0 nylon sutures. In addition, I applied ReSure Sealant (Ocular Therapeutix) to ensure water-tight closure.

Postoperatively, the patient's right eye refracts to 20/25 with -3.00 D. He is deciding how he would like to proceed from a refractive standpoint. ■

#### **Section Editor Lisa Brothers Arbisser, MD**

- emeritus position at Eye Surgeons Associates, the Iowa and Illinois Quad Cities
- adjunct associate professor, John A. Moran Eye Center, University of Utah, Salt Lake City

#### **Section Editor Tal Raviv, MD**

- founder and director, Eye Center of New York
- clinical associate professor of ophthalmology, New York Eye and Ear Infirmary of Mount Sinai

#### **Section Editor Audrey R. Talley Rostov, MD**

- partner, Northwest Eye Surgeons, Seattle
- SightLife global partner
- (206) 528-6000; atalleyrostov@nweyes.com
- financial disclosure: none acknowledged

#### **Nicole R. Fram, MD**

- partner, Advanced Vision Care, Los Angeles
- clinical instructor, Jules Stein Eye Institute, University of California, Los Angeles
- (310) 229-1220; nicfram@yahoo.com
- financial disclosure: speaker for Alcon and Bausch + Lomb

#### **Richard L. Lindstrom, MD**

- founder and attending surgeon, Minnesota Eye Consultants, Minneapolis, Minnesota
- (612) 813-3600; rlindstrom@mneye.com
- financial disclosure: consultant to Abbott Medical Optics, Alcon, and Bausch + Lomb

#### **Cathleen M. McCabe, MD**

- cataract and refractive specialist practicing at The Eye Associates in Bradenton and Sarasota, Florida
- (941) 792-2020; cmccabe13@hotmail.com; Twitter @CathyEye
- financial disclosure: consultant to and speaker for Abbott Medical Optics, Alcon, and Bausch + Lomb